

12-1-2018

Section: Botany, Microbiology and Zoology

THE FIRST REPORT OF INTESTINAL MICROSPORIDIA FROM WILD MAMMALS IN EGYPT 1- LIGHT MICROSCOPY

Mahmoud Younes

Department of Zoology, Faculty of Science, Al-Azhar University, Nasr City, Cairo, Egypt, 11884

Mahmoud Gad

Environmental Parasitology Laboratory, Department of Water Pollution Research, National Research Centre, Dokki, Giza, Egypt, 12622

Ahmed Abdel-Aziz

Department of Zoology, Faculty of Science, Al-Azhar University, Nasr City, Cairo, Egypt, 11884

Ahmed Ismaeil

Department of Zoology, Faculty of Science, Al-Azhar University, Nasr City, Cairo, Egypt, 11884

Ahmad Al-Herrawy

Environmental Parasitology Laboratory, Department of Water Pollution Research, National Research Centre, Dokki, Giza, Egypt, 12622

Follow this and additional works at: <https://absb.researchcommons.org/journal>



Part of the [Life Sciences Commons](#)

How to Cite This Article

Younes, Mahmoud; Gad, Mahmoud; Abdel-Aziz, Ahmed; Ismaeil, Ahmed; and Al-Herrawy, Ahmad (2018) "THE FIRST REPORT OF INTESTINAL MICROSPORIDIA FROM WILD MAMMALS IN EGYPT 1- LIGHT MICROSCOPY," *Al-Azhar Bulletin of Science*: Vol. 29: Iss. 2, Article 29.
DOI: <https://doi.org/10.21608/absb.2018.33814>

This Original Article is brought to you for free and open access by Al-Azhar Bulletin of Science. It has been accepted for inclusion in Al-Azhar Bulletin of Science by an authorized editor of Al-Azhar Bulletin of Science. For more information, please contact kh_Mekheimer@azhar.edu.eg.

THE FIRST REPORT OF INTESTINAL MICROSPORIDIA FROM WILD MAMMALS IN EGYPT 1- LIGHT MICROSCOPY

Mahmoud Younes¹, Mahmoud Gad², Ahmed Abdel-Aziz¹, Ahmed Ismaeil¹ and Ahmad Al-Herrawy²

¹Department of Zoology, Faculty of Science, Al-Azhar University, Nasr City, Cairo, Egypt, 11884

²Environmental Parasitology Laboratory, Department of Water Pollution Research, National Research Centre, Dokki, Giza, Egypt, 12622

Abstract

The first report about intestinal microsporidia from wild mammals in Egypt is herein present. A total of 134 fecal samples were separately collected from seven different mammalian species located in fifteen different localities, represented Western Desert, Nile Valley and Delta and Eastern Desert of Egypt. Microsporidian spores were obtained from the collected samples using flotation technique and finally stained with modified trichrome (MT). Intestinal microsporidia were detected in 72.39% (97/134) of wild mammals. Moreover, rate of infection with intestinal microsporidia was 72.84% (59/81) in males and 73.08% (38/52) in females. The infection rates of intestinal microsporidia were 91.1%, 73.9%, 73.6%, 70%, 55.6% and 48.1% in red fox *Vulpes vulpes*, the lesser Egyptian gerbil *Gerbillus gerbillus*, the house mouse *Mus musculus*, Sundevall's jird *Meriones crassus*, Mackilligin's gerbil *Dipodillus mackilligini* and the Cairo spiny mouse *Acomys cahirinus*, respectively. The results also showed that the highest percentage of microsporidia was recorded in two mammalian species closely related to human habitats: red fox *V. vulpes* and *G. gerbillus*. In conclusion, the wild mammalian species which live in association with humans and fed on their contaminated diets were more susceptible to be infected with several microsporidian species than the other species that live in natural habitats away from humans.

Key words : Microsporidia, Wild mammals, *Vulpes vulpes*

1. INTRODUCTION

Microsporidia are a worldwide group of obligate intracellular microorganisms that infect most animal groups. Wildlife mammals take an attention as a source of significant environmental reservoir of some microsporidian species. There are two main clades of microsporidia: typical (or advanced) and atypical (or primitive) (Vavra and Larsson, 2014). The atypical microsporidia are a small group composed of approximately 13 genera and 42 species (Larsson, 2014). The majority of known microsporidia are of the typical variety, with ~190 genera and an estimated 1300–1500 species (Vavra and Lukes, 2013). *Enterocytozoon bieneusi* and *Encephalitozoon cuniculi*, *E. intestinalis* and *E. hellem* are the four major microsporidia species infecting humans. Of these, the first one *E. bieneusi* is the most frequently diagnosed species of human microsporidia. The first case was found in enterocytes of a Haitian AIDS patient, both genus and species were named by

Desportes *et al.* (1985), based on an electron microscopic morphological study. Further morphological observations placed *E. bieneusi* in the family Enterocytozoonidae (Cali and Owen, 1990). *E. bieneusi* began to be recognized in both domestic and wild animals (Breitenmoser *et al.*, 1999; Mathis *et al.*, 1999). The epidemiology of *E. bieneusi* is still unclear. However, potential sources are beginning to be identified for both humans and a wide range of animals by comparison of *E. bieneusi* ITS genotypes from different hosts.

Microsporidia are increasingly recognized as opportunistic infectious agents worldwide in both developed and developing countries (Stark *et al.*, 2009). In developed countries, the occurrence of microsporidiosis in HIV/AIDS patients is progressively decreasing probably due to access to highly active antiretroviral therapy (HAART) (Weber *et al.*, 1999; van Hal *et al.*, 2007). However, in some developing countries with limited access to HAART, the HIV pandemic continues to spread and

microsporidiosis in AIDS patients still remains high (Fayer and Santin, 2014).

Microsporidia are a diverse group of obligate intracellular pathogens closely related to kingdom Fungi (Fayer and Santin, 2014). *Enterocytozoon bieneusi* is an acellular organism that infects the enterocytes of small intestine and causes diarrhea and enteric diseases in humans, domestic and wild animals (Santin *et al.*, 2010; Santin and Fayer, 2011; Fayer and Santin, 2014). This species is estimated to be responsible for 90% of microsporidian infections including a great number of asymptomatic cases (Metge *et al.*, 2000).

Kicia *et al.* (2018) examined 53 immunocompetent patients for infection by *Encephalitozoon* species. Their findings were 39% (9 samples) had *Encephalitozoon*-positive periprosthetic tissues after revision and 3.3% (1 sample) after primary hip arthroplasty. *Encephalitozoon cuniculi* genotype II was identified in 88.8% (16/18) of samples. Two urine samples were positive for a novel *Encephalitozoon* species.

Ingestion of spores with contaminated foods or water offers the most likely route of transmission of intestinal microsporidia to animals and humans (Stentiford *et al.*, 2016). Besides the oral route, it is possible that aspiration of air contaminated with spores led to infection (Graczyk *et al.*, 2007). There were described several risk factors associated with microsporidian infection: direct person-to-person transmission (Pagornrat *et al.*, 2009), living in rural areas with close contact with animals (i.e. cows, horses, poultry or insects) (Gumbo *et al.*, 1999), consumption of contaminated foods, especially fruits and vegetables (Jędrzejewski *et al.*, 2007). Spores were detected in fresh food produce and were found to be the cause of a dangerous foodborne outbreak in Sweden (Decraene *et al.*, 2012). Other described sources of outbreaks may be non-filtered water in recreational areas like pools, lakes, hot tubs and insufficient hygiene (toilets, garbage and lack of running water) (Gumbo *et al.*, 1999). Species of microsporidia as *E. bieneusi* can be transmitted to humans by

anthroponotic or zoonotic transmission, after exposure to infected individuals or animals, respectively (Matos *et al.*, 2012). Because of its public significance and a great potential threat to the public, according to National Institute of Allergy and Infectious Diseases in the United States, microsporidia are on the priority pathogens list and are considered category B pathogens (Karim *et al.*, 2014).

There are a few epidemiological studies related to microsporidia in wild rodents because of the rodents' low economic importance and also because of the difficulty in conducting such a type of studies (Deng *et al.*, 2016). Studies on *E. bieneusi* from the watershed of New York City's water source revealed that the prevalence of this pathogen among rodents ranged from 20 to 30% and was detected in deer mice *Peromyscus* sp, the boreal red-backed vole *Myodes gapperi* and the meadow vole *Microtus pennsylvanicus* (Guo *et al.*, 2014).

Free-living terrestrial animals have been considered as a significant source of infectious diseases transmitted to humans (Mitkova *et al.*, 2017). Its high level of synanthropization manifested as the gradual colonization of suburban and urban areas may increase the possibility of contact with humans and thus the probability of transfer of pathogenic agents onto both humans and animals. Out of a relatively large percentage of the population of wild carnivorous animals, several species such as the red fox, river otter, raccoon dog or raccoon, and bears were screened for microsporidian species *E. bieneusi* occurrence (Hohmann *et al.*, 2001). Fast increasing populations of red foxes *Vulpes vulpes*, which have become commensal animals in many cases, have been spotted as a major problem throughout Europe (Nowakiewicz *et al.*, 2016). Globally, limited data are available about the prevalence of microsporidia in wild animals while in Egypt, they are absent. So, the objective of the current study was to detect, for the first time, microsporidia from wild mammals from different localities in Egypt.

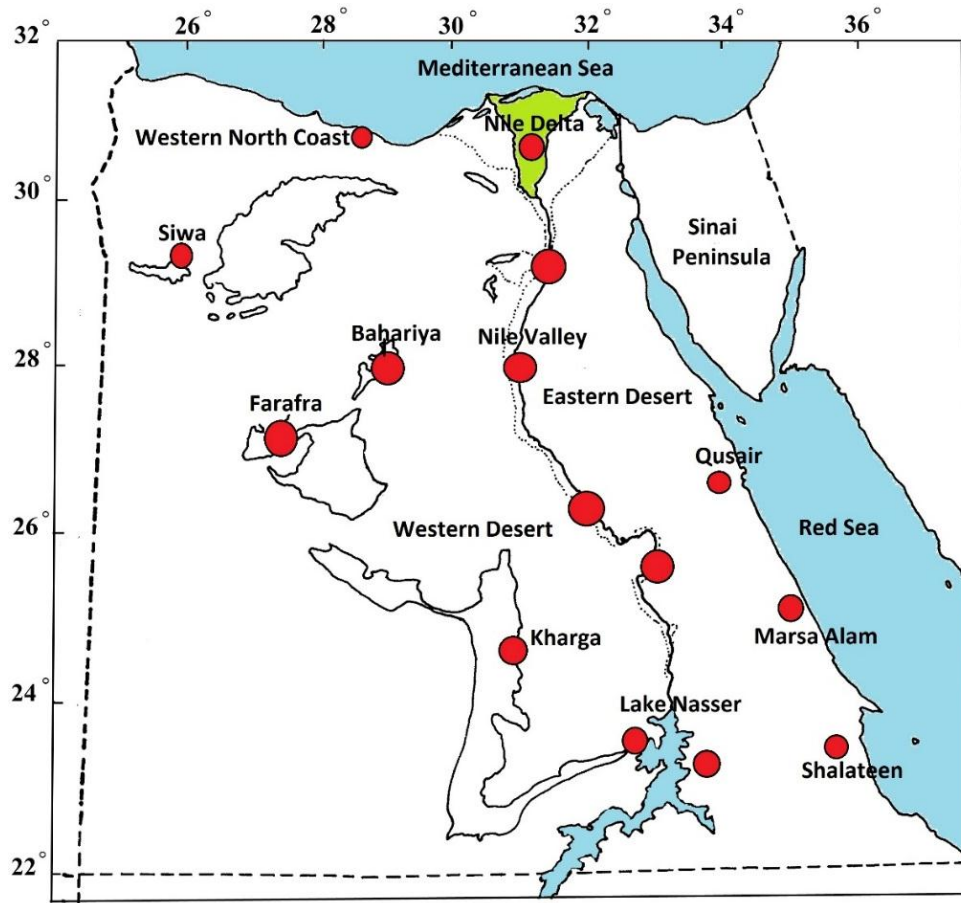


Figure (1): The Egyptian localities of the examined mammals (red circles).

Table (1): The examined wild mammalian species, their numbers and localities

Locality		Species	Examined Number
Western Desert	Western North Coast	<i>Gerbillus gerbillus</i>	4
		<i>Gerbillus andersoni</i>	1
		<i>Vulpes vulpes</i>	5
		<i>Mus musculus</i>	12
	Siwa Oasis	<i>Gerbillus gerbillus</i>	6
	Farafra Oasis	<i>Gerbillus gerbillus</i>	7
		<i>Vulpes vulpes</i>	2
	Bahariya Oasis	<i>Meriones crassus</i>	6
Kharga Oasis	<i>Gerbillus gerbillus</i>	4	
West of Lake Nasser		<i>Gerbillus gerbillus</i>	2
		<i>Mus musculus</i>	7
		<i>Vulpes vulpes</i>	2
Nile Valley and Delta		<i>Vulpes vulpes</i>	28
East of Lake Nasser		<i>Dipodillus mackilligini</i>	2
		<i>Acomys cahirinus</i>	3
		<i>Vulpes vulpes</i>	4
		<i>Acomys cahirinus</i>	15
Eastern Desert	Shalateen	<i>Acomys cahirinus</i>	15
		<i>Meriones crassus</i>	4
	Marsa Alam	<i>Acomys cahirinus</i>	5
		<i>Dipodillus mackilligini</i>	7
	Qusair	<i>Vulpes vulpes</i>	2
	<i>Acomys cahirinus</i>	4	

MATERIALS AND METHODS

Specimens were live-trapped at a number of areas selected to represent some populations of wild mammalian fauna in Egypt for short time to obtain their feces for the investigation, then, they were released. These fauna included the lesser Egyptian gerbil *Gerbillus gerbillus*, Anderson's gerbil *G. andersoni*, Sundevall's jird *Meriones crassus*, Mackilligin's gerbil *Dipodillus mackilligini*, the house mouse *Mus musculus*, the Cairo spiny mouse *Acomys cahirinus* and the red fox *Vulpes vulpes*. The areas of the investigated species were Western Desert, Nile Valley, Delta and Eastern Desert of Egypt (Figure 1 and Table 1).

Several field trips from March 2014 to April 2018 were done to collect the wild animals' samples. Fecal samples of these animals were separately collected and preserved in 10% formalin solution in clean plastic vials. Samples were transferred to the laboratory for investigation.

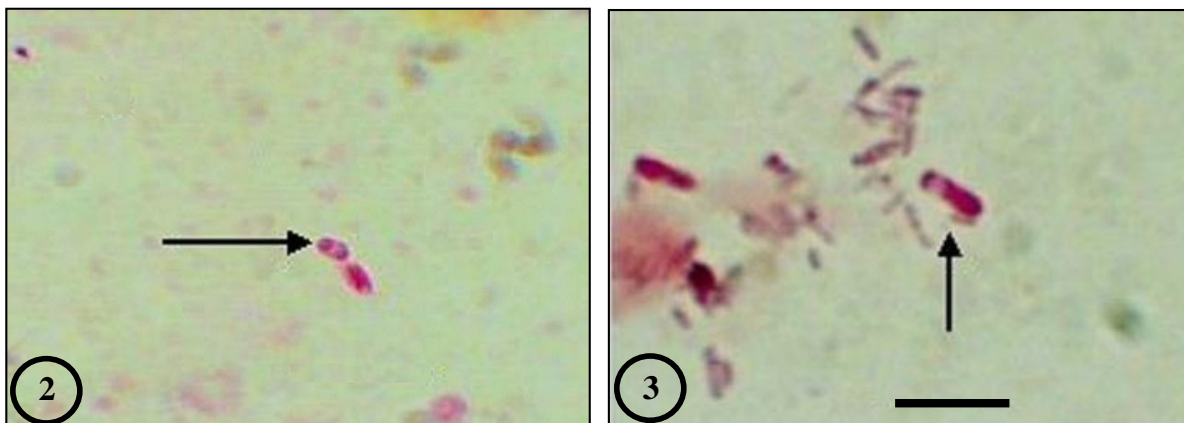
At the laboratory, fecal samples were separately homogenized with a clean spatula and prepared for microscopic detection of microsporidian spores. Ethyl acetate concentration method was used to concentrate spores and fixed on a clean glass slide using absolute methyl alcohol for 30 minutes and stained with modified trichrome (MT) (Weber *et al.*, 1992). Pretreatment of fecal specimens (1:1) with 10% KOH was done to provide a better-quality smear with a modified

trichrome stain. Smears were prepared using 10 to 20 μ l of concentrated fecal solution that was thinly spread onto the slides (Bern *et al.*, 1999).

The modified trichrome stain method was based on the fact that stain penetration of the microsporidian spore is very difficult; thus, the dye content in the chromotrope 2R component of the formula is greater than that used to prepare Wheatley's modification of the Gomori's trichrome stain, and the staining time is much longer (90 min) (Weber *et al.*, 1992; Ryan *et al.*, 1993). Stained smears were carefully examined using a light microscope with an oil immersion lens for the presence of microsporidian spores.

RESULTS AND DISCUSSION

Fecal samples of 134 wild mammal specimens were collected from 15 different localities of Egypt. These localities included the Western and Eastern deserts, Nile Valley and Delta (Figure 1 and Table 1). The large number (45 specimens) of the collected fecal samples was that of the red fox *Vulpes vulpes*, which was the only species collected from all the mentioned regions. The red fox is considered as worldwide distributed and commensal animal, and companion to human. The second large number (27 specimens) of this collection was that of the Cairo spiny mouse *Acomys cahirinus*. However, this species was only collected from Eastern Desert because it lives only in rocky habitats (Table 1).



Figures (2 and 3): Photomicrographs showing pinkish to red spores of intestinal microsporidia, characterizing with a vacuole and with different sizes MT stain. Bar=5 μ m.

Microsporidian spores stained with MT, appeared pinkish to red with clearly identified edges. The interior of the spore being clear showing a horizontal or diagonal stripe, which represented the polar tube. Spore also contained a posterior vacuole against a green counterstained background (Figures 2 and 3). Bacteria, some yeast cells, and some debris were also, stained pinkish to red, however, spore shape and the presence of the posterior vacuole were helpful in differentiating microsporidian spores from these structures (Weber *et al.*, 1992).

Microscopic examination of fecal samples of 134 different wild animals (using a modified trichrome stain) revealed the presence of intestinal microsporidia in 72.39% (n=97). The rate of infection with intestinal microsporidia was 72.84% (59/81) in males and 73.08% (38/52) in females. The infection rates of intestinal microsporidia were 91.1%, 73.9%, 73.6%, 70%, 55.6% and 48.1% in the red fox *Vulpes vulpes*, the lesser Egyptian gerbil *Gerbillus gerbillus*, the house mouse *Mus musculus*, Sundevall's jird *Meriones crassus*, Mackilligin's gerbil *Dipodillus mackilligini* and the Cairo spiny mouse *Acomys cahirinus*, respectively (Table 2 and Figure 4).

Intestinal microsporidia were found in 12/18 fecal specimens (66.7%) of *G. gerbillus* males and 5/5 specimens (100%) in female individuals. Whereas, the infection rate of intestinal microsporidia in *Meriones crassus* was 100% (4 specimens) in male and 50% (3 specimens) in female individuals. These two desert wild species were typically found in dry sandy or rocky areas, sometimes with sparse and coarse vegetation. They were also found in areas close to palm groves. The reason of the infection of all female specimens in *G. gerbillus* and male specimens in *Meriones crassus* was unknown. The low percentage detected in *Meriones crassus* female specimens was also unknown. Unfortunately, no previous data were available about the infection of *G. gerbillus* and

Meriones crassus with intestinal microsporidiosis.

The red fox *Vulpes vulpes* has the widest natural distribution of any terrestrial carnivore and possibly any terrestrial mammal in the world (Wozencraft, 2005). In Egypt, this fox has been recorded from Sinai, Eastern Desert, Nile Delta, Nile Valley and Western Desert (Osborn and Helmy, 1980; Saleh and Basuony, 1998) and is by far the most numerous and widespread carnivore in Egypt (Osborn and Helmy, 1980). Despite the great diversity of habitats occupied by this fox in Egypt, all accounts referred to that there was no significant morphological difference between its populations in different parts of the country. This fox *V. vulpes* was found infected with the highest percentage of intestinal microsporidia in the current study.

Very little is known about microsporidia from wild mammals all over the world. Furthermore, nothing is known about wild mammals' microsporidia in Egypt. In this study, the prevalence of microsporidian spores in the red fox was 91.3% (n=21/23) and 90.9% (n=20/22) in female and male fecal samples, respectively (Table 2 and Figure 4). In the United Kingdom, Wilson (1979) was detected encephalitozoon-like organisms by light microscopy in brain tissues from a wild hand-reared red fox *Vulpes vulpes* with neurological symptoms. In Iceland, antibodies of *Encephalitozoon cuniculi* were found in 11% (41/372) wild arctic foxes *Alopex lagopus*, (Hersteinsson *et al.*, 1993). In Ireland, Murphy *et al.* (2007) reported that microsporidian DNA was amplified from the brains of two samples of the red fox *Vulpes vulpes*. The sequencing of these amplicons revealed 100% homology with *Encephalitozoon intestinalis* in one fox and *Encephalitozoon cuniculi* in the second fox.

However, Loreset *et al.* (2002) in Spain found a lower incidence 5.9% of intestinal microsporidia in dogs (from the same family: Canidae) using Weber's chromotrope stain. In

Portugal, a lower incidence 5/36 (13.8%) of intestinal microsporidia was detected in dogs using MT stain (Lobo *et al.*, 2003). The variation between the current results and that of the previous ones might be attributed to the difference in the numbers or the species of the examined animals.

M. musculus is a small rodent, it is one of the most abundant species of genus *Mus*, and mainly lives in association with humans. It was noticed that intestinal microsporidiosis in the house mouse *Mus musculus* was higher in male (75%, n=9/12) than in female individuals (71.43%, n=5/7). In Iceland, Hersteinsson *et al.* (1993) were found microsporidian spores of *Encephalitozoon cuniculi* in only 8.51% (4/47) of the wild house mice *M. musculus*. Whereas, in an area at the Czech Republic–German border, 14.5% (42/289) fecal samples from wild house mice *M. musculus* were positive by PCR for *Encephalitozoon cuniculi* (Sak *et al.*, 2011). In this study, the high percentage found in both the red fox *V. vulpes* and the house mouse *M. musculus* might be due to their lives

in association with humans, making these wild animals fed on contaminated diets, and might be infected with several species of intestinal microsporidia.

Concerning Mackilligin's gerbil *Dipodillus mackilligini*, in the current work the highest prevalence of microsporidian spores was detected in 80% (n=4/5) male fecal samples and in 25% (n=1/4) in female fecal samples. Intestinal microsporidia infected 50% (n=10/20) of the Cairo spiny mouse *Acomys cahirinus* males, and 42.86% (n=3/7) of female individuals. No microsporidian spores were found in Anderson's gerbil *Gerbillus andersoni* (n=1) (Table 2 and Figure 4) and this result might be due to that the investigation was done on samples of only one specimen. In Switzerland, seropositive have been previously detected in the wild rat *Rattus norvegicus*, where 13% (3/23) of them were seropositive, and a microsporidian *Encephalitozoon cuniculi* was isolated from the brain of one of these rodents (Muller-Doblies *et al.*, 2002).

Table (2): Prevalence of intestinal microsporidia in wild mammals' fecal samples.

Total number of the examined species	+ ve in female	+ ve in male	Species
23	5/5 (100%)	12/18 (66.7%)	The lesser Egyptian gerbil (<i>Gerbillus gerbillus</i>)
10	3/6 (50%)	(100%) 4/4	Sundevall's jird (<i>Meriones crassus</i>)
45	21/23 (91.3%)	20/22 (90.9%)	The red fox (<i>Vulpes vulpes</i>)
9	1/4 (25%)	4/5 (80%)	Mackilligin's gerbil (<i>Dipodillus mackilligini</i>)
19	5/7 (71.43%)	9/12 (75%)	The house mouse (<i>Mus musculus</i>)
27	3/7 (42.86%)	10/20 (50%)	The Cairo spiny mouse (<i>Acomys cahirinus</i>)
1	0	0	Anderson's gerbil (<i>Gerbillus andersoni</i>)
134	38/52 (73.08%)	59/81 (72.84%)	Total

CONCLUSION

The wild mammalian species live in association with humans and fed on their contaminated diets were more susceptible to be infected with several species of microsporidia than other species that live in natural habitats away from humans. The red fox *Vulpes vulpes* was the most species infected with intestinal microsporidia among the tested wild animals. The appearance of virulent microsporidia in wild animals pointed to the contamination of their environment.

ACKNOWLEDGMENT

The authors are very grateful to Dr. Mostafa Saleh, Professor at Department of Zoology, Faculty of Science, Al-Azhar University, Cairo, Egypt for his help to collect the study specimens.

REFERENCES

- Bern, C.; Hernandez, B.; Lopez, M. B.; Arrowood, M. J.; de Mejia, M. A.; de Merida, A. M.; Hightower, A. W.; Venczel, L.; Herwaldt, B. L. and Klein, R. E. (1999): Epidemiologic study of *Cyclospora cayatanensis* in Guatemala. *Emerging Infectious Diseases*, 5: 766-774.
- Breitenmoser, A. C.; Mathis, A.; Bürgi, E.; Weber, R. and Deplazes, P. (1999): High prevalence of *Enterocytozoon bieneusi* in swine with four genotypes that differ from those identified in humans. *Parasitology*, 118: 447-453.
- Cali, A. and Owen, R. L. (1990): Intracellular development of *Enterocytozoon*, a unique microsporidian found in the intestine of AIDS patients. *Journal of Protozoology*, 37: 145-155.
- Decraene, V.; Lebbad, M.; Botero-Kleiven, S.; Gustavsson, A. M. and Lofdahl, M. (2012): First reported foodborne outbreak associated with microsporidia, Sweden. *Epidemiology and Infection*, 140: 519-527.
- Deng, L.; Li, W.; Yu, X.; Gong, C.; Liu, X.; Zhong, Z.; Xie, N.; Lei, S.; Yu, J.; Fu, H.; Chen, H.; Xu, H.; Hu, Y. and Peng, G. (2016). First report of the human-pathogenic *Enterocytozoon bieneusi* from red-bellied tree squirrels (*Callosciurus erythraeus*) in Sichuan, China. *PLoS One*, 11: e0163605.
- Desportes, I.; Le Charpentier, Y.; Galian, A.; Bernard, F.; Cochand-Priollet, B.; Lavergne, A.; Ravisse, P. and Modigliani, R. (1985): Occurrence of a new microsporidian: *Enterocytozoon bieneusi* n. g., n. sp., in the enterocytes of a human patient with AIDS. *Journal of Protozoology*, 32: 250-254.
- Fayer, R. and Santin, M. (2014): Epidemiology of Microsporidia in human infections. In: *Microsporidia: Pathogens of opportunity*. (Eds. Louis M. Weiss and James J. Becnel). Wiley Blackwell, pp 135-164.
- Graczyk, T. K.; Johansson, M.A.; Tamang, L.; Visvesvara, G. S.; Moura, L. S.; DaSilva, A. J.; Girouard, A. S. and Matos, O. (2007): Retrospective species identification of microsporidian spores in diarrheic fecal samples from human immunodeficiency virus/AIDS patients by multiplexed fluorescence in situ hybridization. *Journal of Clinical Microbiology*, 45: 1255-1260.
- Gumbo, T.; Sarbah, S.; Gangaidzo, I. T.; Ortega, Y.; Sterling, C. R.; Carville, A.; Tzipori, S. and Wiest, P. M. (1999). Intestinal parasites in patients with diarrhea and human immunodeficiency virus infection in Zimbabwe. *Journal of Acquired Immune Deficiency Syndromes*, 13: 819-821.
- Guo, Y.; Alderisio, K.A.; Yang, W.; Cama, V.; Feng, Y. and Xiao, L. (2014). Host specificity and source of *Enterocytozoon bieneusi* genotypes in a drinking source watershed. *Applied and Environmental Microbiology*, 80: 218-225.
- Hersteinsson, P.; Gunnarsson, E.; Hjartardottir, S. and Skirnisson, K. (1993): Prevalence of *Encephalitozoon cuniculi* antibodies in terrestrial mammals in Iceland, 1986 to 1989. *Journal of Wildlife Diseases*. 29: 341-344.
- Hohmann, U.; Voigt, S. and Andreas, U. (2001): Quo vadis raccoon? New visitors in our backyards - on the urbanization of an allochthonic carnivore in Germany. In: *Naturschutz und Verhalten*. (Eds. Gottschalk E., Barkow A., Muhlenberg M., and Settele J.). Lepzig, UFZ Berichte: pp 143-148.
- Jędrzejewski, S.; Graczyk, T.; Słodkiewicz-Kowalska, A.; Tamang, L. and Majewska, A. C. (2007): Quantitative assessment of contamination of fresh food produce of various retail types by human-virulent microsporidian spores. *Applied and Environmental Microbiology*, 73: 4071-4073.

- Karim, M. R.; Wang, R.; Dong, H.; Zhang, L.; Li, J.; Zhang, S.; Rume, F. I.; Qi, M.; Jian, F.; Sun, M.; Yang, G.; Zou, F.; Ning, C. and Xiao, L. (2014): Genetic polymorphism and zoonotic potential of *Enterocytozoon bieneusi* from nonhuman primates in China. *Applied and Environmental Microbiology*, 80: 1893-1898.
- Kicia, M.; Wesolowska, M.; Kopacz, Z.; Kváč, M.; Sak, B.; Sokulska, M.; Cebulski, K.; Hendrich, A. B. and Pozowski, A. (2018): Disseminated Infection of *Encephalitozoon cuniculi* Associated With Osteolysis of Hip Periprosthetic Tissue. *Clinical Infectious Diseases*, 67: 1228-1234.
- Larsson, J. I. (2014): The primitive microsporidia. In *Microsporidia: Pathogens of Opportunity* (Weiss, L. and Becnel, J.J., eds) pp. 605–634, John Wiley & Sons.
- Lobo, M. L.; Teles, A.; da Cunha, M. B.; Henriques, J.; Lourenço, A. M.; Antunes, F. and Matos, O. (2003): Microsporidia detection in stools from pets and animals from the zoo in Portugal: A preliminary study. *Journal of Eukaryotic Microbiology*, 50: 581-582.
- Lores, B.; del Aguila, C. and Arias, C. (2002): *Enterocytozoon bieneusi* (Microsporidia) in fecal samples from domestic animals from Galicia, Spain. *The Memórias do Instituto Oswaldo Cruz*, 97: 941-945.
- Mathis, A.; Breitenmoser, A. C. and Deplazes, P. (1999): Detection of new *Enterocytozoon* genotypes in fecal samples of farm dogs and a cat. *Parasite*, 6: 189–193.
- Matos, O.; Lobo, M. L. and Xiao, L. (2012): Epidemiology of *Enterocytozoon bieneusi* infection in humans. *Journal of Parasitology Research*, Article ID 981424, 19 pages doi:10.1155/2012/981424
- Metge, S.; Nhieu, J. T.; Dahmane, D.; Grimbert, P.; Foulet, F.; Sarfati, C. and Bretagne, S. (2000): A case of *Enterocytozoon bieneusi* infection in an HIV-negative renal transplant recipient. *European Journal of Clinical Microbiology and Infectious Diseases*, 19: 221-223.
- Mitkova, B.; Hrazdilova, K.; D'Amico, G.; Duscher, G. G.; Suchentrunk, F.; Forejtek, P.; Gherman, C. M.; Matei, I. A.; Ionică, A. M.; Daskalaki, A. A.; Mihalca, A. D.; Votycka, J.; Hulva, P. and Modry, D. (2017): Eurasian golden jackal as host of canine vector-borne protists. *Parasites and Vectors*, 10: 183-193.
- Muller-Doblies, U. U.; Herzog, K.; Tanner, I.; Mathis, A. and Deplazes, P. (2002): First isolation and characterization of *Encephalitozoon cuniculi* from a free-ranging rat (*Rattus norvegicus*). *Veterinary Parasitology*, 107: 279–285.
- Murphy, T. M.; Walochnik, J.; Hassl, A.; Moriarty, J.; Mooney, J.; Toolan, D.; Sanchez-Miguel, C.; O'Loughlin, A. and McAuliffe, A. (2007): Study on the prevalence of *Toxoplasma gondii* and *Neospora caninum* and molecular evidence of *Encephalitozoon cuniculi* and *Encephalitozoon (Septata) intestinalis* infections in red foxes (*Vulpes vulpes*) in rural Ireland. *Veterinary Parasitology*, 146: 227-234.
- Nowakiewicz, A.; Zięba, P.; Ziolkowska, G.; Gnat, S.; Muszyńska, M.; Tomczuk, K.; Majer-Dziedzic, B.; Ulbrich, Ł. and Trościańczyk, A. (2016): Free-living species of carnivorous mammals in Poland: red fox, beech marten and raccoon as a potential reservoir of *Salmonella*, *Yersinia*, *Listeria* spp. and coagulase-positive *Staphylococcus*. *PLoS One*, 11: e0155533.
- Osborn, D. and Helmy, I. (1980): The contemporary land mammals of Egypt (including Sinai). *Fieldiana Zoology, New Series*, No. 5.
- Pagornrat, W.; Leelayoova, S.; Rangsin, R.; Tan-Ariya, P.; Naaglor, T. and Mungthin, M. (2009): Carriage rate of *Enterocytozoon bieneusi* in an orphanage in Bangkok, Thailand. *Journal of Clinical Microbiology*, 47: 3739-3741.
- Ryan, N. J.; Sutherland, G.; Coughlan, K.; Globan, M.; Doultree, J.; Marshall, J.; Baird, R. W.; Pedersen, J. and Dwyer, B. (1993): A new trichrome-blue stain for detection of microsporidial species in urine, stool, and nasopharyngeal specimens. *Journal of Clinical Microbiology*, 31: 3264-3269.
- Sak, B.; Kvac, M.; Kvetonova, D.; Albrecht, T. and Pialek, J. (2011): The first report on natural *Enterocytozoon bieneusi* and *Encephalitozoon spp.* infections in wild East-European house mice (*Mus musculus musculus*) and West-European house mice (*M. m. domesticus*) in a hybrid zone across the Czech Republic-Germany border. *Veterinary Parasitology*, 178: 246–250.
- Saleh, M. A. and Basuony, M. I. (1998): A contribution to the mammalogy of the Sinai Peninsula. *Mammalia*, 62(4): 121-135.
- Santin, M. and Fayer, R. (2011): Microsporidiosis: *Enterocytozoon bieneusi* in domesticated and wild animals. *Research in Veterinary Science*, 90: 363-371.

- Santin, M.; Vecino J. A. and Fayer, R. (2010): A zoonotic genotype of *Enterocytozoon bieneusi* in horses. *Journal of Parasitology*, 96: 157-161.
- Stark, D.; Barratt, J. L.; van Hal, S.; Marriott, D.; Harkness, J. and Ellis, J. T. (2009): Clinical significance of enteric protozoa in the immunosuppressed human population. *Clinical Microbiology Reviews*, 22: 634-650.
- Stentiford, G. D.; Becnel, J. J.; Weiss, L. M.; Keeling, P. J.; Didier, E. S.; Williams, B. A.; Bjornson, S.; Kent, M. L.; Freeman, M. A., Brown, M. J.; Troemel, E. R.; Roesel, K.; Sokolova, Y.; Snowden, K. F. and Solter, L. (2016): Microsporidia – emergent pathogens in the global food chain. *Trends in Parasitology*, 32: 336-348.
- van Hal, S. J.; Muthiah, K.; Matthews, G.; Harkness, J.; Stark, D.; Cooper, D. and Marriott, D. (2007): Declining incidence of intestinal microsporidiosis and reduction in AIDS-related mortality following introduction of HAART in Sydney, Australia. *Transactions of the Royal Society of Tropical Medicine and Hygiene*, 101: 1096–1100.
- Vavra, J. and Larsson, J. I. (2014): Structure of microsporidia. In *Microsporidia: Pathogens of Opportunity* (Weiss, L. and Becnel, J.J., eds), pp. 1–70, John Wiley & Sons.
- Vavra, J. and Lukes, J. (2013): Microsporidia and the art of living together. *Advanced Parasitology*, 82: 254–319.
- Weber, R.; Bryan, R. T.; Owen, R. L.; Wilcox, C. M.; Gorelkin, L. and Visvesvara, G. S. (1992): Improved light-microscopical detection of Microsporidia spores in stool and duodenal aspirates. *The New England Journal of Medicine*, 326: 161-166.
- Weber, R.; Ledergerber, B.; Zbinden, R.; Altwegg, M.; Pfyffer, G. E. Spycher, M. A; Briner, J.; Kaiser, L.; Opravil, M.; Meyenberger, C. and Flepp, M. (1999): Enteric infections and diarrhea in human immunodeficiency virus-infected persons: prospective community-based cohort study. *Swiss HIV Cohort Study. Archives of Internal Medicine*, 159: 1473–1480.
- Wilson, J. M. (1979): *Encephalitozoon cuniculi* in wild European rabbits and a fox. *Research in Veterinary Science*, 26: 114.
- Wozencraft, W. C. (2005): Order Carnivora. In: Wilson, D. E. and Reeder, D. M. (eds.) *Mammal Species of the World, Third Edition*.
- The Johns Hopkins University Press, Baltimore, 532-628.