

6-1-2008

Section: Botany, Microbiology and Zoology

PROTECTIVE EFFECT OF **B**-CAROTENE ON GAMMA RADIATION-INDUCED RENAL HISTOLOGICAL AND ULTRASTRUCTURAL CHANGES IN MALE ALBINO RATS

SEHAM ABU-NOUR

National Center for Radiation Research and Technology (NCRRT), Atomic Energy Authority (AEA), Cairo, Egypt

MOHAMED RADY

Zoology Department, Faculty of Science, Al-Azhar University, Cairo, Egypt.

IHAB KHALIL

National Center for Radiation Research and Technology (NCRRT), Atomic Energy Authority (AEA), Cairo, Egypt.

Follow this and additional works at: <https://absb.researchcommons.org/journal>



Part of the [Life Sciences Commons](#)

How to Cite This Article

ABU-NOUR, SEHAM; RADY, MOHAMED; and KHALIL, IHAB (2008) "PROTECTIVE EFFECT OF B-CAROTENE ON GAMMA RADIATION- INDUCED RENAL HISTOLOGICAL AND ULTRASTRUCTURAL CHANGES IN MALE ALBINO RATS," *Al-Azhar Bulletin of Science*: Vol. 19: Iss. 1, Article 6.

DOI: <https://doi.org/10.21608/absb.2008.10498>

This Original Article is brought to you for free and open access by Al-Azhar Bulletin of Science. It has been accepted for inclusion in Al-Azhar Bulletin of Science by an authorized editor of Al-Azhar Bulletin of Science. For more information, please contact kh_Mekheimer@azhar.edu.eg.

PROTECTIVE EFFECT OF B-CAROTENE ON GAMMA RADIATION-INDUCED RENAL HISTOLOGICAL AND ULTRASTRUCTURAL CHANGES IN MALE ALBINO RATS

*SEHAM M. ABU-NOUR; **MOHAMED I. RADY AND *IHAB M. KHALIL

**National Center for Radiation Research and Technology (NCRRT), Atomic Energy Authority (AEA) and **Zoology Department, Faculty of Science, Al-Azhar University.*

Abstract

The present work was conducted to investigate the histological and ultra-structural changes in the kidney tissues of male albino rats due to the exposure of gamma-radiation and to investigate tissue-protection from the damaging effects of gamma-radiation using a natural product namely, Beta-carotene.

The histological studies revealed progressive pathological lesions in the kidney of whole body γ -irradiated rats; as represented by severe damage in glomerular tuft and increase in mesangial cells with wide Bowman's space and severe hemorrhagic areas between degenerated renal tissue, and renal tubules exhibited various degrees of degeneration. The ultra-structural studies revealed that epithelial cells lining the proximal and distal convoluted tubules exhibited an increase in the swelling mitochondria, dilation in the rough endoplasmic reticulum and electron dense in the nuclear chromatin. Thickness in basement membrane, dilation of infolded, and damage of brush border of the proximal tubules were also observed. The treatment with β -carotene pre-exposure to gamma radiation attenuated most of these changes. Therefore, the present study has implication for the potential use of β -carotene as a radioprotector.

Introduction

A wealth of experimental data has clearly demonstrated that renal irradiation leads to progressive and dose-dependent alterations in renal structures and functions. Gamma-irradiation has major histological and physiological effects on kidney; Traver *et al.* (2004) stated that the mammalian kidney is among the most radiosensitive organs in the abdomen. Some scientists focused research on the renal diseases induced by kidney irradiation as a clinic- pathologic study on the human; Dewit *et al.* (1990) found that radiation injury to the renal parenchyma is an unusual cause of renal insufficiency. Soranson and Denekamp (1986) declared that the tubular cells are among the most important target cells for radiation injury in the kidney. Robbins *et al.* (1995 and 2002) found that the renal irradiation resulted in a progressive decline in glomerular filtration rate (GFR) and effective renal plasma flow (ERPF). Also they confirmed that the renal irradiation resulted in significant

alterations in the glomerular and tubular cell proliferation and morphology within 2-4 weeks of irradiation. Abu-Nour (2002) recorded that whole body Gamma-irradiation of mice induced definite microscopic changes in kidney represented by degeneration of convoluted tubules. Also, El-Sayed (2004) stated that kidney sections of post-irradiated rat's revealed obvious degenerative features.

Many synthetic antioxidant components have shown toxic and/or mutagenic effects, which have directed most attention on naturally occurring antioxidant Kumar *et al.* (2007). The antioxidant capacity of carotenes against free radicals and oxidative damage was widely studied by many authors. Carotene intake prevents skin lipid peroxidation caused by UV irradiation (Someya *et al.*, 1994), contributes to the defense of membrane against oxidative stress, antioxidants reduces the mutagenicity of many chemicals and offers a significant protection against the generation of single strand breaks of DNA (Sarkar *et al.*, 1997).

After higher irradiation doses the drugs became less effective in protecting the kidney's tissue and fibrosis induced due to gamma-irradiation (Martin *et al.*, 2001). Beta-carotene (Pro-vitamin A) enables the body to produce vitamin A as this nutrient is needed (Solomons, 2001). Also beta-carotene is highly effective quencher of singlet oxygen and a direct scavenger of free radicals. Beta-carotene survives the process of absorbing singlet oxygen intact. Therefore, a single molecule of beta-carotene can arrest up to 1,000 molecules of singlet oxygen (Gaby and Singh, 1991 and Tesoriere *et al.*, 1995).

Hence, the present study hypothesized that Beta-carotene, because of its antiperoxidative and scavenger effects may be useful to prevent ionizing radiation-induced renal histological changes.

Materials And Methods

Forty adult male albino rats (*Rattus norvegicus*) of about 180 ± 15 g body weight were obtained from the animal Breeding House of the National Research Center, Dokki, Cairo, Egypt. Animals were housed in metal cages for one week, as an acclimatization period, under the laboratory conditions. Rats were fed a commercial balanced diet, and allowed free to excess of water. Abnormally noticed animals were eliminated. Thereafter, the animals (36) were divided into four groups. Group 1 (6 animals): the animals served as a control group. Group 2 (6 animals): the animals received 5mg/kg b.wt. of β -carotene at a daily oral dose for 2 weeks. Group 3 (12 animals): the animals subjected to whole body γ -irradiation at a sub-lethal single dose level of 6Gy and then divided into four equal subgroups; the first subgroup was

sacrificed after one day, the second after one week, the third after two weeks and the fourth after four weeks post irradiation. Group 4 (12 animals): The animals received β -carotene at a daily oral dose 5mg/kg b.wt. for 2 weeks, then subjected to whole body γ -irradiation at a sub-lethal single dose level of 6Gy. This group was divided into four equal subgroups; the first subgroup was sacrificed after one day, the second after one week, the third after two weeks and the fourth after four weeks post irradiation.

Whole body γ -irradiation was performed using Cesium 137 Biological γ -cell-40 irradiation facility belonging to The National Center for Radiation Research and Technology (NCRRT). Whole body γ -irradiation was delivered for the necessary calculated time for the sub-lethal dose level of 6Gy (single dose). The dose rate was equal to 0.908 rad/sec. The material used in the present investigation as a protective agent was β -carotene. That was manufactured by Fulka Co. Switzerland. It was diluted with corn oil at reasonably dilute concentration. The kidney of control and treated animals were dissected out and washed in normal saline, then cut into pieces and put in suitable fixatives. For routine histopathological evaluation under light microscopy; the fixative used was 10% buffered formalin, sections stained with haematoxylin and eosin (Lillie, 1954). Some tissue samples were examined by transmission electron microscope (TEM) JEOL (JEM 100CX) at NCRRT. Glutaraldehyde (4%) buffered with 0.2 M sodium cacodylate; then Osmium tetroxide (2%) buffered with 0.3 M sodium cacodylate were used. A series of ethyl alcohol was used for dehydration and the specimens were embedded in a resin, Araldite-Epon Kit (EMBed 812) methods recommended by Hayat (1981).

Results

The kidney of control rat showed normal structures of the renal cortex which comprised renal corpuscles, proximal and distal convoluted tubules (Fig. 1). No pathological changes were observed in the kidney of rats which received 5mg/kg b. wt/day of beta-carotene for 2 weeks in comparison with the control group. Whole body γ -irradiation of rats with a single dose of 6 Gy at the 1st day post exposure, induced bleeding and some lesions in the renal tubules (Fig. 2). Whereas, 1 week after irradiation showed progressive pathological lesions represented by sever damage in glomerular tuft with wide Bowman's space and sever bleeding scattered in between degenerated renal tissue (Fig. 3). Two weeks post-irradiation of rats pointed out atrophy in gromerular tuft with widening in the glomerular space, rupture in Bowman's capsule, an increase in masengal cells, hemorrhage lesion, destruction of cells lining the proximal and the distal tubules (Fig.4). 4th week post-

irradiation, some destruction occurred in glomerular corpuscles and rupture in Bowman's capsule was found. In addition, some renal tubules were degenerated and hemorrhagic areas were presented in between (Fig.5). Rats treated with Beta-carotene for 2 weeks before exposure to γ -irradiation induced at 1st day post-irradiation, an improvement in renal corpuscles and regeneration in epithelial convoluted tubules (Fig.6). 1 week post-irradiation revealed an improvement in the glomerular tuft with normal Bowman's space, intact Bowman's capsule as well as proliferation of mesangial cells with rupture in some renal tubules (Fig. 7). After 2 weeks of irradiation, some changes were still noticed in the renal tissues, in comparison with the control group, while some glomerular tufts were lobulated and there was increase in the cellularity. Also, there was a slight degeneration in the renal tubular epithelial cells (Fig. 8). 4 weeks post-irradiation, examination showed repair in convoluted tubular epithelial cells but shrinkage in glomerular tuft with rupture in Bowman's capsule were seen (Fig. 9).

Electron microscopic study of the cortex of the control group recorded that the proximal convoluted tubules were lined by large cells with basal membrane infoldings and elongated mitochondria. The nuclei appeared rounded, vesicular with smooth nuclear membrane (Fig. 10). One cell of distal convoluted tubules showed spherical euchromatic nuclei while the other showed clumped heterochromatin and few apical microvilli. The cells showed also extensive basal infolding between elongated basal mitochondria (Fig. 11). Rats exposed to whole body γ -irradiation, exhibited after 4 weeks sever degeneration in the proximal and distal tubules. Ultra-structural changes were detected in the epithelial cells lining the proximal convoluted tubules showing an increase in the swelling mitochondria with rupture of its cristae. Also, there was dilation in the rough endoplasmic reticulum and electron dense nuclear chromatin. Thickness in basement membrane and dilation of infolding were observed. The damage of brush boarder was also noticed (Figs. 12). The epithelial cells lining the distal convoluted tubules showed pyknotic nuclei and ill-defined cytoplasmic organelles also damage in basement membrane were also detected, in addition collagen fibers were seen (Fig. 13). Rats orally treated with Beta-carotene pre-irradiation revealed an improvement of proximal convoluted tubules. Normal round shape nucleus was observed. Also, the sections revealed an improvement of epical region and regeneration of brush boarder (Fig. 14). In the distal convoluted tubules there were prominent improvements in the basement membrane including normal infolded. Normal round nucleus, normal epical region and normal microvilli were also recorded (Fig. 15).

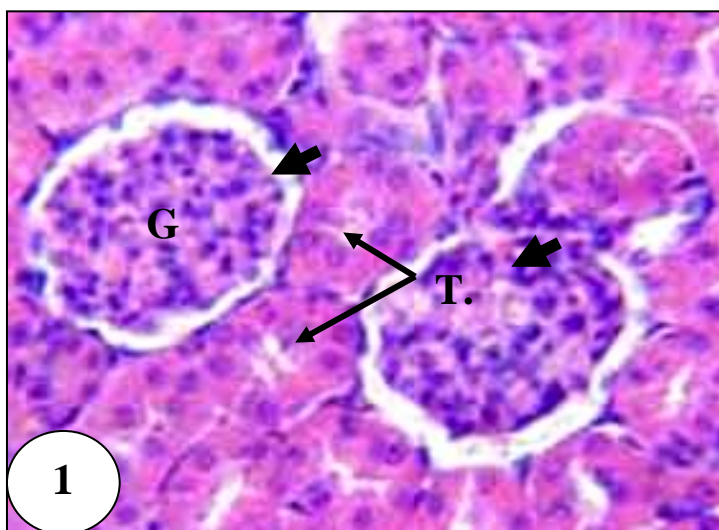


Fig. (1): Photomicrograph of normal kidney section of control rat showing normal renal corpuscles (thick arrows), glomerular tuft (G) and normal renal tubules (T). (H/E X 400).

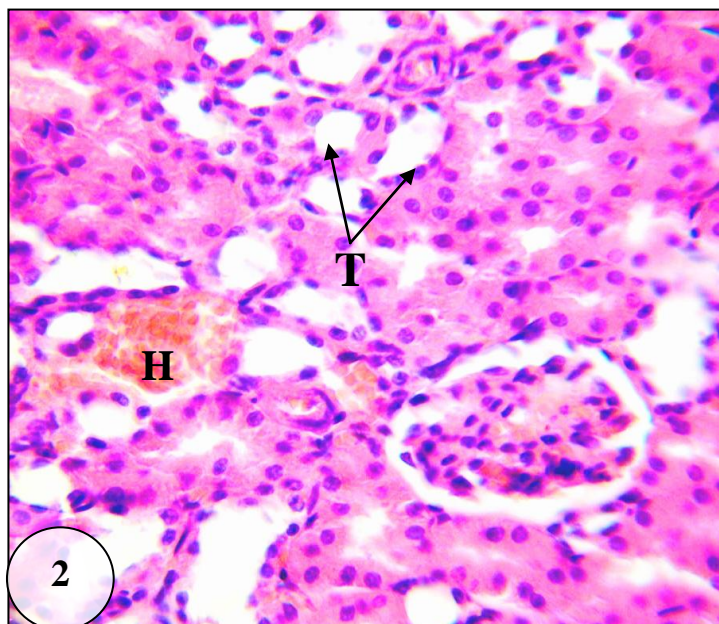


Fig. (2): Photomicrograph of kidney section of irradiated rat 1st day post exposure showing hemorrhagic area (H) between the damaged renal tubules (T). (H/E X 400).

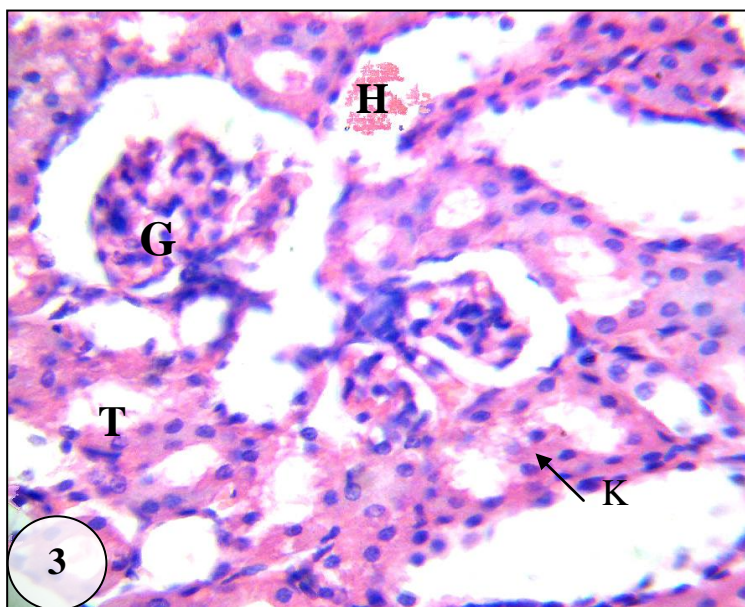


Fig. (3): Photomicrograph of kidney section of irradiated rat with 1 week post exposure showing damage in glomerular tuft (G) karyolysis (K) and damage in the renal tubules (T), plus hemorrhagic area (H) in renal tissue. (H/E X 400).

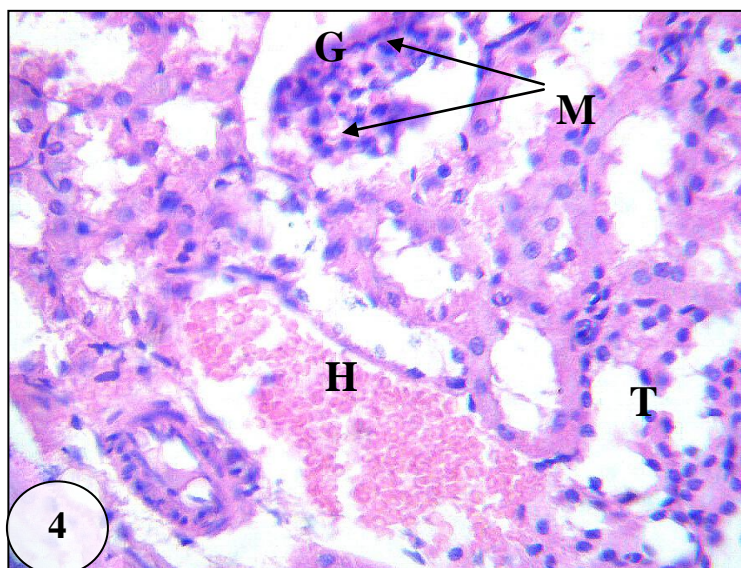


Fig. (4): Photomicrograph of kidney section of irradiated rat with 2 weeks post exposure showing collapse in glomerular tuft (G) and proliferated mesangial cells (M). Note large hemorrhage lesion (H) and rupture and fusion between lumens of convoluted tubules (T). (H/E X 400).

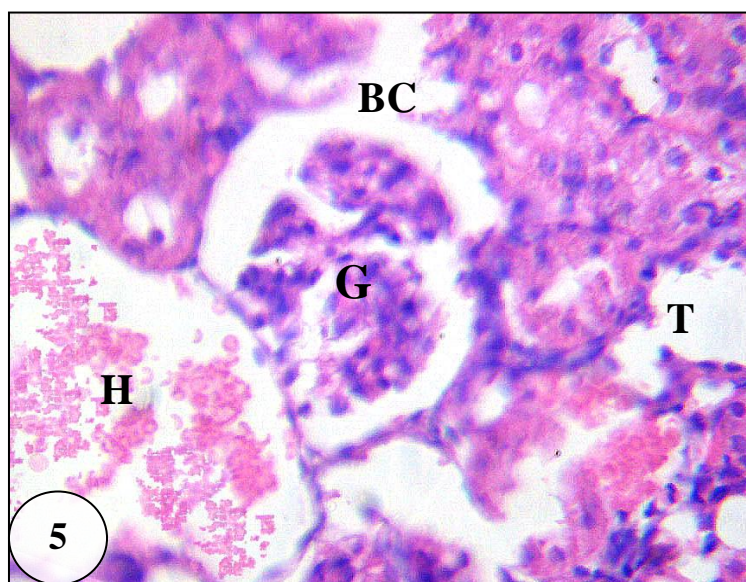


Fig. (5): Photomicrograph of kidney section of irradiated rat 4 weeks post exposure showing damage in glomerular corpuscles (G) and rupture in Bowman's capsule (B.C) with damage in renal tubules (T) and hemorrhage area (H). (H/E X 400).

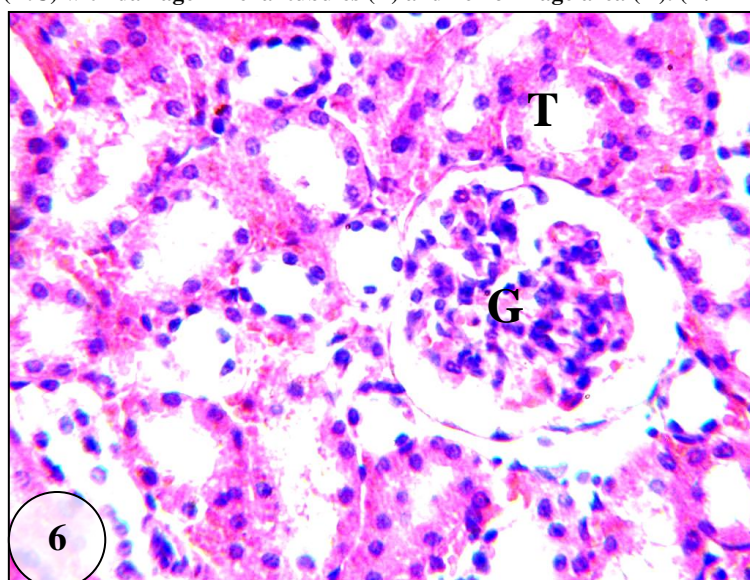


Fig. (6): Photomicrograph of kidney section of treated rat with Beta-carotene pre-irradiation 1st day post exposure showing improvement in renal glomerular corpuscles (G) and regeneration in epithelial convoluted tubules (T). (H/E X 400).

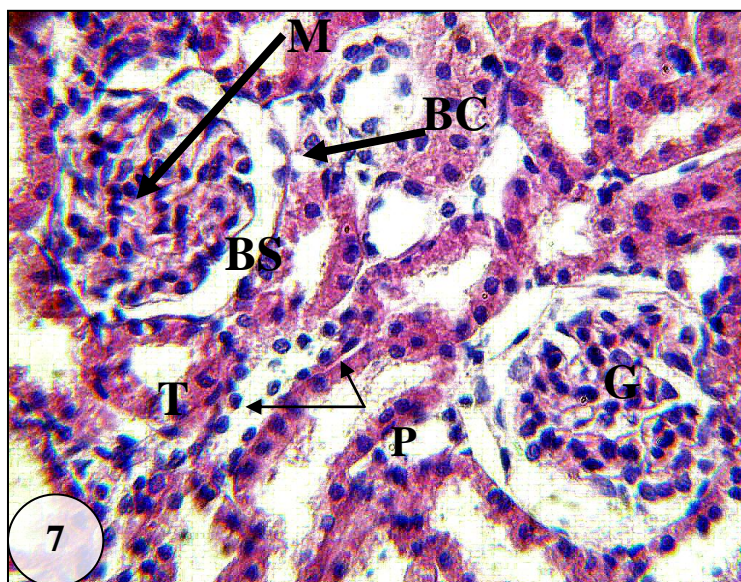


Fig. (7): Photomicrograph of kidney section of treated rat with Beta- -carotene pre-irradiation 1week post exposure showing an improvement in the glomerular tuft (G) with normal Bowman's space (BS) and Bowman's capsule (BC) and proliferation of mesangial cells (M) with rupture in some renal tubule cells (T) and pyknotic nuclei (P). (H/E X 400).

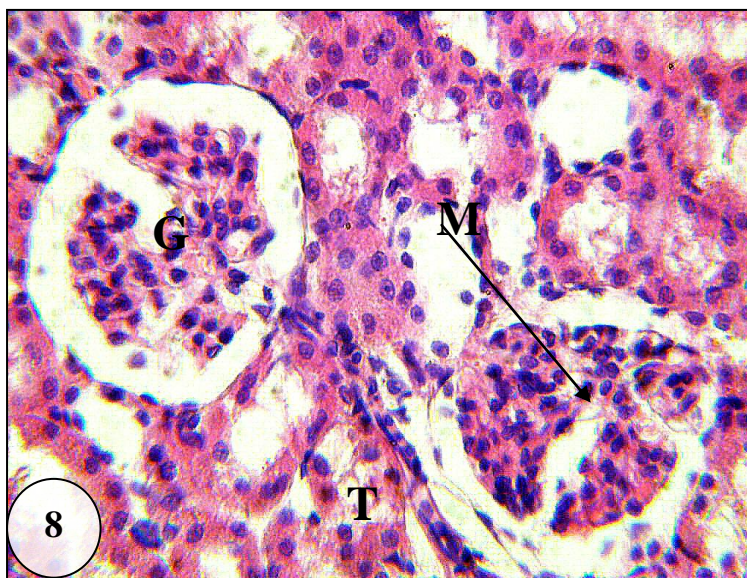


Fig. (8): Photomicrograph of kidney section of treated rat with Beta-carotene pre-irradiation 2 weeks post exposure showing lobulated glomerular tuft (G) with proliferated mesangial cells (M) and some degeneration in renal tubular epithelial cells (T). (H/E X 400).

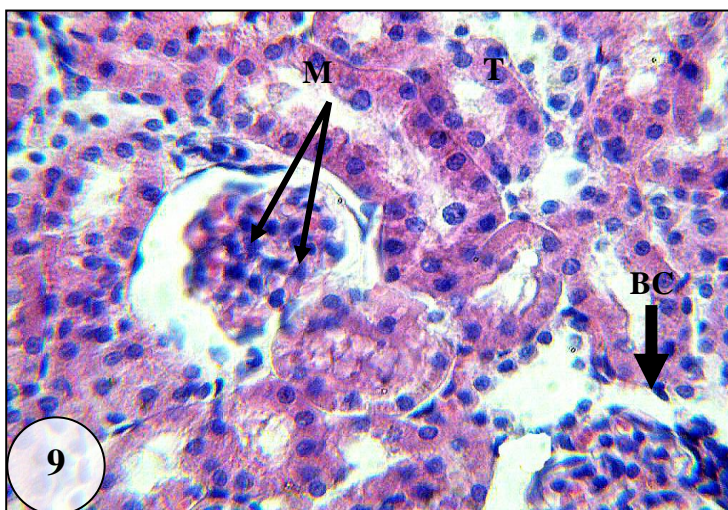


Fig. (9): Photomicrograph of kidney section of treated rat with Beta-carotene pre-irradiation 4 weeks post exposure showing repair in convoluted tubular epithelial cells (T) and shrinkage in glomerular tuft (G) with rupture in Bowman's capsule (BC) and increase in mesangial cells (M). (H/E X 400).

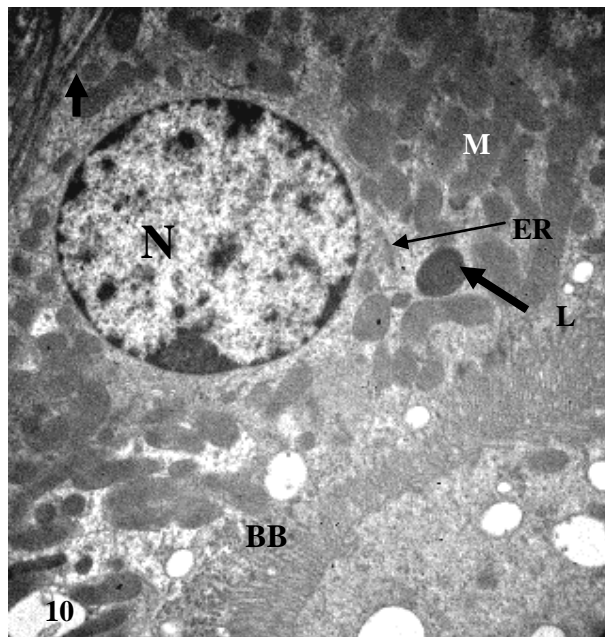


Fig. (10): Electron micrograph of a part of a normal proximal convoluted tubule of albino rat kidney showing basal spherical nucleus (N) with euchromatin and heterochromatin, brush boarder (BB) mitochondria (M), endoplasmic reticulum (ER) and lysosome (L). Note the thin basement membrane (BM) and the normal basal infolding (arrow). (X4600).

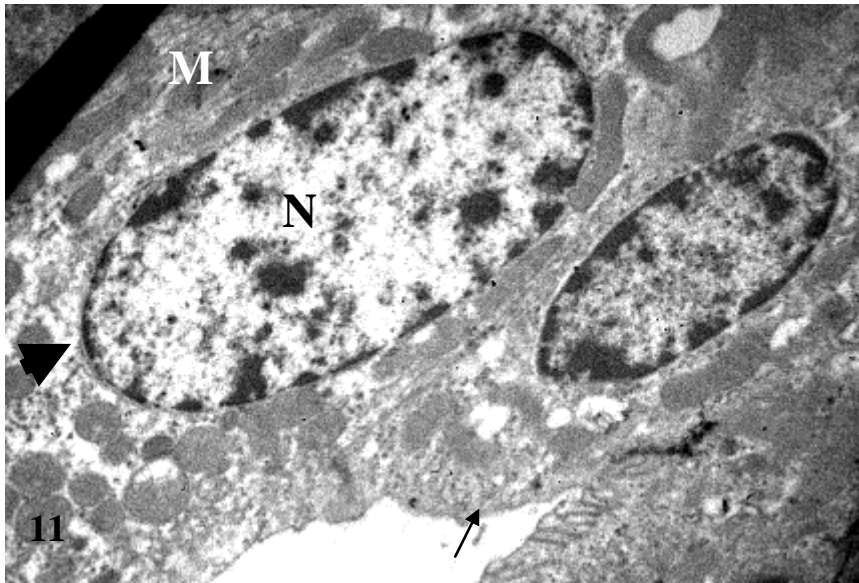


Fig. (11): Electron micrograph of a part of a normal distal convoluted tubule of albino rat kidney showing the apical part with few microvilli (arrow), oval nucleus (N) dilated cisterna of endoplasmic reticulum (head arrow) and many elongated mitochondria (M) arranged in between the numerous basal enfolding (X4600).

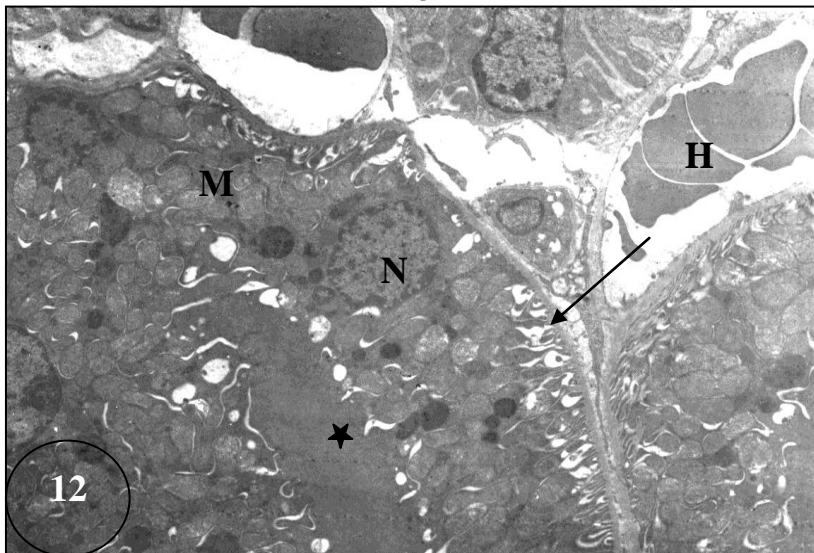


Fig. (12): Electron micrograph of irradiated rat 4 weeks post exposure showing sever degeneration in the proximal tubules, swelling mitochondria (M) with rupture of its cristae, dilatations of rough endoplasmic reticulum and electron dense in the nuclear chromatin (N). Thickness in basement membrane and dilation of infolding (arrow), damage of brush boarder (star) and large area of hemorrhage (H) between renal tubules was noticed. (X 2800).

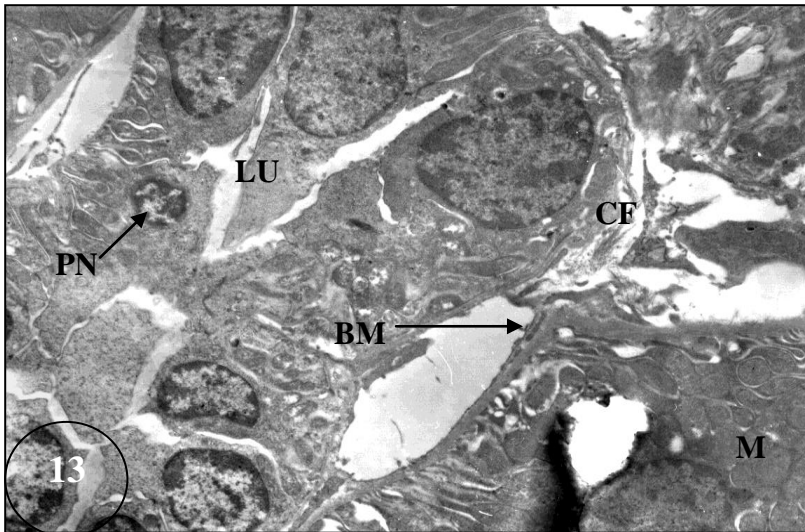


Fig. (13): Electron micrograph of irradiated rat 4 weeks post exposure showing sever degeneration in the distal tubules, degeneration of mitochondria (M), pyknotic nuclei (N) and dilation of rough endoplasmic reticulum, thickness and rupture in basement membrane (BM) and dilated infolded (arrow). Narrow lumen (LU) with hyaline cast and cell debris. The collagen fibers (CF) can be seen near or around the distal tubules (X 3600).

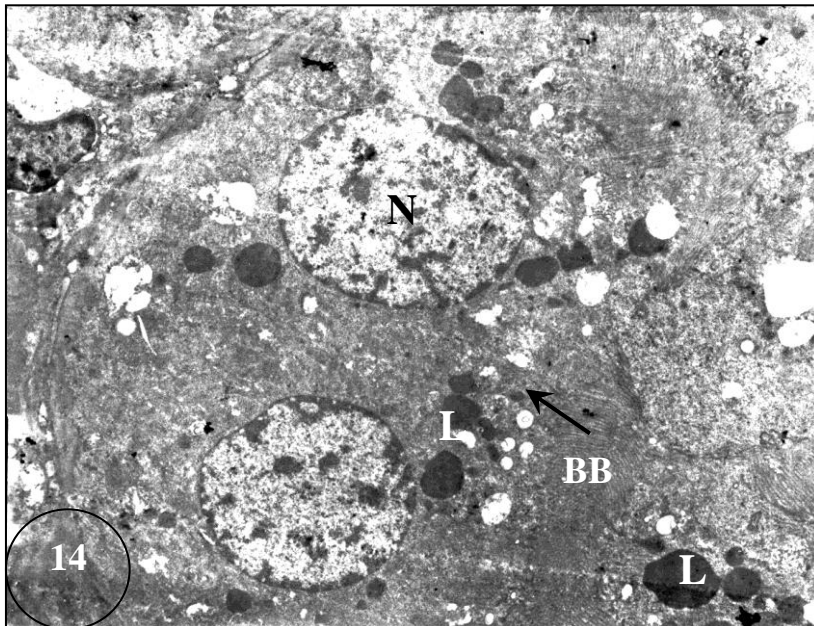


Fig. (14): Electron micrograph of rat treated with Beta-carotene pre-irradiation showing regeneration of proximal convoluted tubule cells, round shape nucleus (N). Improvement of the epical region (arrow) and regeneration of the brush border (BB) and polymorphic lysosomes (L) were noticed. (X 3600).

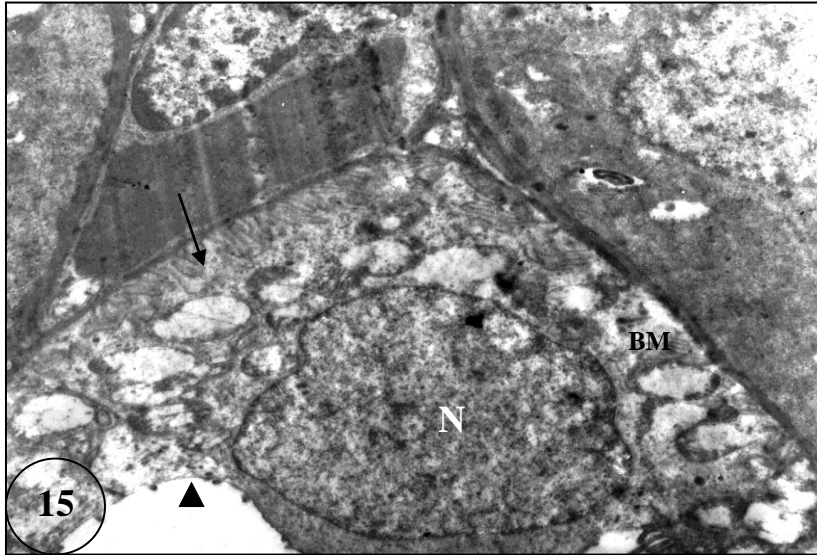


Fig. (15): Electron micrograph of rat treated with Beta-carotene pre-irradiation showing improvement of distal convoluted tubules including intact of basement membrane (BM) with normal infolding (arrow), normal round nucleus (N), normal epical region and normal microvilli (arrow head). (X 6000).

Discussion

Kidney is one of the organs that show high sensitivity toward gamma-radiation (Dewit *et al.*, 1990 and Traver *et al.*, 2004). In the present study damage in glomerular tuft was noticed with widening in Bowman's space then rupture in later stages as a result of gamma-irradiation. This result was in agreement with the finding of Stephens *et al.* (1995) who indicated that, the structural changes have led to the concept that glomeruli appeared to be very radiosensitive because after the clinically relevant dose of 24 Gy in 12 fractions essentially all glomeruli were altered in the irradiated kidneys as compared to controls. The present study also found lobulation and shrinkage in some glomerular tufts with rupture in Bowman's capsule and increase in mesangial cells due to whole body gamma-irradiation in rats. Also, there were marked proliferation of mesangial cells within the glomerular tufts and prominent degeneration in the renal tubular epithelial cells. Robbins *et al.* (1995) mentioned that the renal irradiation resulted in a progressive decline in glomerular filtration rate (GFR), alterations in glomerular and tubular cell proliferation and morphology within 2-4 weeks of irradiation. Irradiation can also induce complete glomerular capillary obstruction due to thrombus formation (Van Kleef *et al.*, 1998). The earliest histological damage due to radiation exposure which

was observed in the present work was noticed in glomerular capillary endothelial cells. In agreement with the present results the experimental data for mice, pigs and primates as well as data from clinical studies suggested that glomerular damage develops before tubular damage (Jaenke *et al.*, 1993 and Robbins *et al.*, 1995) and that glomerular damage is mainly responsible for renal failure (Robbins and Bonsib, 1995).

The present results revealed that glomerular changes were characterized by thickening of glomerular capillary walls, tuft shrinkage and focal sclerosis. Tubular changes were marked by flattening of tubular epithelium, focal cell loss, and focal interstitial fibrosis these results are in agreement with those of Van Kleef *et al.* (1998). Also the emerged results revealed sever hemorrhagic areas scattered in-between degenerated renal tissue, due to gamma-irradiation in rats. Proliferation of the mesangial cells observed in the present study might be a defense mechanism. Destruction of cells lining the proximal and distal tubules was similar to that observed by Soranson and Denekamp (1986) Jaenke *et al.*, (1993) and Abu-Nour (2002). They concluded that the tubular cells are among the most important target cells for radiation injury and the endothelial cell injury represents the primary site of radiation damage in the rat's kidney.

The results of the ultra-structural examinations showed that whole body gamma irradiation of rats induced degeneration in the proximal and distal tubules in the kidneys. These results are in agreement with those of Dewit *et al.* (1990) who reported that kidney is one of the most radiosensitive organs and is dose-limiting in cancer patients treated with total-body or abdominal irradiation. The present results revealed that the epithelial cells lining the proximal convoluted tubules exhibited an increase in the swelling mitochondria with rupture of its cristae; these findings concord with those recorded by Al-Karaz *et al.* (1990) and Thannoo *et al.* (1996). Moreover, Ghadially (1988) referred that, the mitochondrial swelling and destruction of their cristae are due to the influx of water into the inner and outer mitochondrial chambers, which is accompanied by separation of the inner and outer mitochondrial membranes. Since mitochondria are the site of the main energy production in the cell, their damage may result in lowered energy out put. Therefore, the failure of the mitochondrial activity in the damaged cells may be regarded as a factor causing cell degeneration.

Also the present results revealed dilation in the rough endoplasmic reticulum induced from exposure to 6 Gy of gamma-radiation. Similar changes were also

reported by Huijbers *et al.* (1979) who reported that, the damage of the rough endoplasmic reticulum (RER) reflects the impairment of protein synthesis in such cells. In the present study whole body γ -irradiation in rats induced damage in the proximal and distal convoluted tubules and showed destruction of brush boarder and microvilli. These changes could be attributed to the degenerative changes involving the whole tubules as well as to thickening of tubular basement membrane, in accordance with Huijbers *et al.* (1979) and Cohen (2000). Also, ultra-structural studies carried on gamma-irradiated albino rats showed that, focal tubular alterations were detected (Mulder *et al.* 2002). At the 6th day, and 10th week, electron dense material within lysosomes of tubular cells was detected. The present results revealed that, there was a relation between exposure to whole body gamma-irradiation and the alterations which were induced in the structure of renal tissues and consequently impairment of its functions as regarded by Kapyaho *et al.* (1983).

The present results proved that β -carotene can act effectively as radio-protector and showed that the treatment with β -carotene for two weeks prior to gamma irradiation decreases the harmful effects of radiation exposure. Its working mechanism depends on scavenging the free radicals and quenching the singlet oxygen (Gaby and Singh, 1991; Someya *et al.*, 1994; Tesoriere *et al.*, 1995 and Dokmeci *et al.*, 2006). Also, examination of kidney sections demonstrated an improvement in renal corpuscles, thin membrane of Bowman's capsule with intact Bowman's capsule and regeneration in epithelial convoluted tubules were observed. However, some histopathological changes still noticed in the renal tissues, in comparison with the control group. So, beta-carotene has shown to have a good antioxidant effect by reducing the effect of gamma-radiation on the kidney of rats. Also, ultrastructurally, an improvement in proximal and distal convoluted tubule epithelial cells was noticed, normal round shape nucleus was observed and improvements in the epical region and microvilli of the cells in addition to regeneration of brush boarder were perceptive.

The capacity of glomerular cells to generate reactive oxygen species in response to several stimuli independently of infiltrating polymorphonuclear leukocytes and monocytes suggests that reactive oxygen species may also play an important role in renal injury (Gonzalez *et al.*, 1996). Also, Park *et al.* (2007) reported that the cytotoxic effect of radiation is propagated through reactive oxygen species (ROS) and ROS-driven oxidative stress. Manda and Bhatia (2003) indicated that, the antioxidant property of beta-carotene against gamma radiation could be due to free radical scavenging capacity and singlet oxygen quenching. The antioxidant and

protective properties of organic compounds led to the conclusion that these compounds prevent the development of subsequent oxidizing chain reactions (Zhuravlev, 1987). Satyamitra *et al* (2001) and Cherdyntseva *et al* (2005) found that some vitamins induce excellent protection against radiation exposure hazards. In coincidence with the present data Tukulenko *et al.* (2006) found that, Beta-carotene demonstrated the largest protective effect alone and as a component in complex compound.

In conclusion, Beta-carotene administration to rats prior to exposure to ionizing radiation could minimize the harmful and deleterious effects on rat kidney. It is therefore suggested that beta-carotene could be considered as an effective antioxidant that could scavenge free radicals and active oxygen species that were formed in the animal body as a result of gamma radiation exposure

References

1. Abu-Nour, S.M. (2002): Radio-protective effect of garlic-oil on the kidney of male albino mice. (Histological and Histochemical studies). J. Egypt. Ger. Soc. Zool.; 39(C): 391-410.
2. Al-Karaz, M.; Meseguer, J. and Garacia, A. (1990): Effect of radiation on rabbit thyroid gland ultra-structure. J. Sunmicroscope. Cytol. Pathol.; 22(3): 433-440.
3. Cherdyntseva, N.; Shishkina, A.; Butorin, I.; Murase, H.; Gervas, P. and Kagiya, T.V. (2005): Effect of tocopherol-monoglucoside (TMG), a water-soluble glycosylated derivate of vitamin E, on hematopoietic recovery in irradiated mice. J. Rad. Res. (Tokyo); 46(1): 37-41.
4. Cohen, E.P. (2000): Radiation nephropathy after bone marrow transplantation. Kidney Int. J.; 58: 903-918.
5. Dewit, L.; Anninga, J.K.; Hoefnagel, C.A. and Nooijen, W.J. (1990): Radiation injury in the human kidney; a prospective analysis using specific scintigraphic and biochemical endpoints. Int. J. Rad. Biol. Physic., 19: 977-983.
6. Dokmeci, D.; Akpolat, M.; Aydogdu, N.; Uzal, C.; Doganay, L. and Turan, F. (2006): The protective effect of L-carnitine on ionizing radiation-induced free oxygen radicals. Scand. J. Lab. Anim. Sci.; 33(2): 75-83.
7. El-Sayed, N.M. (2004): Efficiency of 6, 8- dithio-octanoic acid (Lipoic Acid) boosting protective antioxidation capacity in irradiated rats. Arab J. of Nuc. Sci. Appl., 37(1): 313-320.
8. Gaby, S.K. and Singh, V.N. (1991): Premalignant lesions: role of antioxidant vitamins and beta-carotene in risk reduction and prevention of malignant transformation. Am. J. Clin. Nutr.; 53(1 Suppl.): 386S-390S.

9. Ghadially, F.N. (1988): Ultra-structural pathology of the cell and matrix. Butterworth, London.
10. Gonzalez, M.; Voit, S.; Rodriguez, D.R.; Weber, M. and Marx, M. (1996): Oxidative stress induces tyrosine phosphorylation of PDGF receptors in mesangial cells. *Kidney Int. J.*; 95: 50.
11. Hayat, M.A. (1981): Fixation for Electron Microscopy. 501 pp., Academic press New York
12. Huijbers, W.A.; Oosterbaan, J.A.; Haarsma, T.J.; Hardonk, M.J. and Molenaar, I. (1979): An ultrastructural and cytochemical study of membrane alterations in x-irradiated liver tissue from normal and vitamin E deficient ducklings. *Rad. Res.*; 78: 502-513.
13. Jaenke, R.S.; Robbins, M.E.; Bywaters, T.; Whitehouse, E.; Rezvani, M. and Hopewell, J.W. (1993): Capillary endothelium. Target site of renal radiation injury. *Lab. Invest.*; 68: 396-405.
14. Kapyaho, K.; Lauharanta, J. and Janne, J. (1983): Inhibition of DNA protein synthesis in UV irradiated mouse skin by 2-difluoromethyl ornithine, methylglyoxalbis (Guanyldiazotone) and their combination. *J. Invest. Derm.*; 81: 102-106.
15. Kumar, M.; Samarth, R.; Kumar, M.; Selvan, S.; Saharan, S. and Kumar, A. (2007): Protective effect of *Adhatoda vasica* leaves against radiation-induced damage at cellular, biochemical and chromosomal levels in Swiss albino mice. *eCAM*; 4(3): 343-350.
16. Lillie, R.D. (1954): Histopathological techniques and practical histochemistry. Mc Grow-Hill, U.S.A.
17. Manda, K. and Bhatia, A.L. (2003): Pre-administration of beta-carotene protects tissue glutathione and lipid peroxidation status following exposure to gamma radiation. *J. Environ. Biol.*; 24(4): 369-372
18. Martin, M.; Delanian, S.; Sivan, V.; Vozenin, B.M.C.; Reisdorf, P.; Lawrance, D. and Lefaix, J.L. (2001): Radiation induced fibrosis and TGF- α 1. *Cancer Radiother.*; 4(5): 369-384
19. Mulder, A.S.; Pallauf, J. and Most, E. (2002): Parameters of dietary selenium and vitamin E deficiency in growing rabbits. *J. Trace Elem. Med. Biol.*; 16(1): 47-55.
20. Park, E.; Ramnath, N.; Yang, G.; Ahn, J.; Park, Y.; Lee, T.; Shin, H.; Clement, J. and Park, Y. (2007): High superoxide dismutase and low glutathione peroxidase activities in red blood cells predict susceptibility of lung cancer patients to radiation pneumonitis. *Free Radical Biology & Medicine*, 42: 280-287.
21. Robbins, M.E and Bonsib, S.M. (1995): Radiation and nephropathy: a review. *Scanning Microsc.*; 9(2): 535-560.
22. Robbins, M.E.; Stephens, L.C., Thames, H.D.; Gray, K.N.; Peters, L.J. and Ang, K.K. (1995): Radiation response of the monkey kidney following contra lateral nephrectomy. *Int. J. Radiat. Oncol. Biol. Phys.*; 30: 347-354.

23. Robbins, M.E.; Zhao, W.A; Davis, C.S.; Toyokuni, S. and Bonsib, S.M. (2002): Radiation-induced kidney injury: a role for chronic oxidative stress. *Micron.*; 33(2): 133-141.
24. Sarkar, A.; Basak, R.; Bishayee, A.; Basak, J. and Chatterjee, M. (1997): Beta-carotene inhibits rat liver chromosomal aberrations and DNA chain break after a single injection of diethylnitrosamine. *Br. J. Cancer.*, 76 (7): 855-861.
25. Satyamitra, M.; Devi, P.U.; Murase, H. and Kagiya, V.T. (2001): In vivo radioprotection by alpha-TMG: preliminary studies. *Mutat. Res.*; 479(1-2): 53-61.
26. Solomons, N.W. (2001): Vitamin A and carotenoids. In: BA Bowman and RM Russell, eds. *Present Knowledge in Nutrition*, 8th edition. Washington, DC: ILSI Press, pp. 127-139.
27. Someya, K.; Totsuka, Y.; Murakoshi, M.; Kitano, H. and Miyazawa, T. (1994): The antioxidant effect of palm fruit carotene on skin lipid peroxidation in guinea pigs as estimated by chemiluminescence-HPLC method. *J. Nutr. Sci. Vitaminol. (Tokyo)*; 40 (4): 315-324.
28. Soranson, J. and Denekamp, J., (1986): Precipitation of latent renal radiation injury by unilateral nephrectomy. *Br. J. Cancer.*; 53: 268-272.
29. Stephens, L.C.; Robbins, M.E.; Thames, H.D.; Johnson, A.D.; Price, A.R.; Peters, L.J. and Ang, K.K. (1995): Radiation nephropathy in the rhesus monkey: Morphometric analysis of glomerular and tubular alterations. *Int. J. Rad. Oncol. Biol. Phys.*; 31: 865-873.
30. Tesoriere, L.; Bongiorno, A.; Remy, R. and Livrea, M.A. (1995): Reciprocal protective effects of all-trans retinol and alpha-tocopherol during lipid peroxidation in retinal membranes. *Biochem. Mol. Biol. Int.*; 37(1): 1-7.
31. Thannoo, D.R.; Paquet, F.; Berry, J.P. and Galle, P. (1996): Early ultrastructural lesions of kidney cells after intravenous administration of 239 plutonium citrate in rats. *C. R. Acad. Sci. III.*; 319(2): 119-123.
32. Traver, D.; Winzeler, A.; Stern, H.; Mayhall, E.; Langenau, D.; Kutok, J.; Thomas, A. and Zon, L. (2004): Effects of lethal irradiation in zebrafish and rescue by hematopoietic cell transplantation. *Blood*; 104: 1298-1305.
33. Tukalenko, Ie.V. ; Varets'kyi, V.V.; Rakochi, O.H.; Dmytriieva, I.R. and Makarchuk; M.Iu. (2006): Antioxidant modification of ionizing irradiation and additional stress effects on higher nervous activity in rats. *Fiziol Zh.*; 52(4): 33-39.
34. Van Kleef, B.M.; J.A.M.; Poele, Y.; Oussoren, M.; Verheij, I.; Van de Pavert, S.J.; Braunhut, L.G.H. and Dewit E.A. (1998): Increased expression of glomerular von Willebrand factor after irradiation of the mouse kidney. *Rad. Res.*; 150: 528-53.
35. Zhuravlev, K.I. (1987): Effect of ionizing radiation on physico-chemical and organoleptic properties of sunflower oil. *Vopr. Pitan.*; 16(4): 60-64.

الملخص العربي

تأثير حماية البيتا-كاروتين على التغيرات الهستولوجية والتراكيب الدقيقة في كلى ذكور الجرذان البيضاء المعرضة لأشعة جاما

* سهام محمد أبو نور، * محمد إبراهيم راضى و * إيهاب محمد خليل
* المركز القومي لبحوث وتكنولوجيا الإشعاع - هيئة الطاقة الذرية
* قسم علم الحيوان - كلية العلوم - جامعة الأزهر

هدفت الدراسة الى تقييم التأثير الوقائى للبيتا-كاروتين ضد الأضرار الناتجة من التعرض لأشعة جاما، استخدم فى هذه الدراسة ستة و ثلاثون جرذاً أبيضاً، قسمت إلى أربع مجموعات رئيسية: - المجموعة الأولى: وتتضمن ستة جرذان كعينة ضابطة. المجموعة الثانية: وتتضمن ستة جرذان تم إعطائها 5مجم/كجم من وزن الجسم من البيتا- كاروتين فى جرعة يومية لمدة أسبوعين، المجموعة الثالثة وتتضمن 12 جرذاً وتم تعريضها الى جرعة (6 جراى) من أشعة جاما ثم تقسيمها بعد ذلك الى أربع مجموعات متساوية. المجموعة الرابعة وتتضمن 12 جرذاً تم إعطائها البيتا- كاروتين بالإضافة لتعرضها لأشعة جاما، ثم تم تقسيمها الى أربع مجموعات متساوية. تم أخذ العينات على أربع فترات متتالية، بعد يوم، و أسبوع، وأسبوعين ثم بعد أربعة أسابيع.

أظهرت النتائج أن أنسجة كلى الجرذان التي تعرضت لأشعة جاما بجرعة (6 جراى) حدث بها تحلل فى أنسجة الكلى ونزيف وانكماش للكبيبات مع إتساع فى كبسولة بومان و دمار فى خلايا الأنابيب الملتفة. ولقد سجلت صور الميكروسكوب الالكتروني تحلل فى الأنابيب الملتفة و إنتفاخات فى الميتوكوندريا وحدوث تكسير فى الحواجز الداخلية لها وزيادة فى أعداد الأجسام المحللة وتفتت فى الشبكة الإندوبلازمية الخشنة و تكثف لكروماتين الأنوية. كما لوحظ زيادة فى سمك الغشاء القاعدى للخلية.

أما المجموعات التي عولجت بالبيتا-كاروتين قبل تعرضها لأشعة جاما فقد وجد أن نسيج الكلى حافظ على مكوناته الخلوية و حدث إعادة شفاء سريع لما قد تأثر بالإشعاع إلى حد كبير. ولهذا يمكن الاستدلال من هذه الدراسة على أهمية الدور المؤثر للبيتا-كاروتين كعلاج وقائى ضد الأضرار الناتجة من التعرض لأشعة جاما.